

Name \_\_\_\_\_

Date \_\_\_\_\_

Literacy Lab #23: "Dental X-Rays...tumor"

Living Environment: Comet 2011-2012

## **"Dental X-Rays Linked To Common Brain Tumor, Study Finds"**

**Directions:** Take a few minutes to read the article below either online (or on the back of this page.) Write responses to the statements or questions below. Cut/copy/paste is not allowed – use your own words and thoughts, based in research if needed.

Read more: [http://www.huffingtonpost.com/2012/04/10/dental-x-rays-brain-tumor\\_n\\_1413158.html](http://www.huffingtonpost.com/2012/04/10/dental-x-rays-brain-tumor_n_1413158.html)

**Fact-finding:** List three facts that you learned in this article.

1.

2.

3.

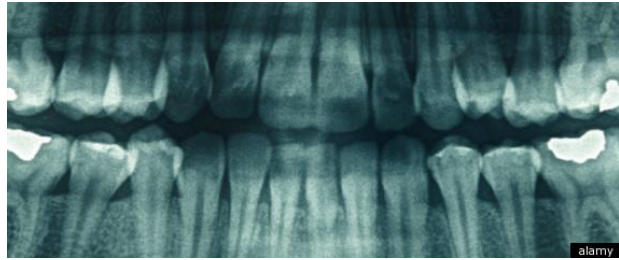
**Vocabulary:** List and define three unfamiliar words in the space below.

**Implications:** What are your feelings about this "discovery"? Why is this type of discovery important/unimportant? Fully explain your answers.

## “Dental X-Rays Linked To Common Brain Tumor, Study Finds”

Dental X-rays may help dentists collect essential information about oral health, but a new study is raising questions about their safety.

The new research links regular dental imaging to one of the most common types of brain tumors and suggests adults who were regularly exposed to X-rays in the past, before dosages were lowered, might have an especially pronounced risk.



For the new study, scheduled to be published online on Tuesday in the the American Cancer Society's journal *Cancer*, researchers examined data from more than 1,400 patients who had been diagnosed with meningioma: This is a type of tumor that grows in membranes surrounding the brain and spinal cord and generally is noncancerous, but can lead to headaches, vision and memory problems and loss of speech and motor control. The researchers compared those individuals to more than 1,300 adults who were tumor-free.

Adults who developed brain tumors were more than twice as likely to say that they had bitewing X-rays yearly, if not more frequently, according to the findings. Bitewing X-rays, which require patients to bite down on an X-ray film holder, show the crowns of the upper and lower teeth at the same time.

The researchers also found a link between the tumors and panorex dental exams, which use an X-ray outside the mouth to take a broad image of a patient's full mouth and are often used to look at problems such as infections and fractures. The increased risk of meningioma was particularly pronounced among individuals who were younger than 10 when they received the exam.

Dr. John B. Ludlow, a professor of oral and maxillofacial radiology at the University of North Carolina who was not associated with the study, said that it revealed a statistical association between a history of dental X-rays and meningiomas that he called "thought provoking, if not sobering."

He cautioned, however, that dental techniques have changed over the years.

"Given the relatively long time frame between exposure to ionizing radiation and appearance of solid tumor cancers, most of the cases in the [study] received dental x-ray exposures two or more decades prior to the appearance of a tumor," Ludlow stated in an email to *The Huffington Post*. In the past, the film was slower, meaning patients underwent X-ray radiation for a longer time, while newer units have reduced exposure in other ways, he said.

"It is important to keep diagnostic imaging risks in perspective," Ludlow said.

The American Dental Association, the world's largest national dental society, says that the number of times the average person undergoes X-rays depends on a slew of factors, including their age, risk for disease and overall oral health. Its guidelines for dentists, last revised in 2004, state that practitioners must weigh the benefits of taking X-rays against the risk of exposure -- with the effects accumulating over time.

"My view is if an X-ray is necessary for medical treatment, then one should go ahead and get that X-ray," said Dr. Keith L. Black, chairman and professor in the department of neurosurgery at Cedars-Sinai

Medical Center. The current study is not the first to look at the possible association but is among the largest and best designed, he said.

"If I was going to get a root canal and I needed an X-ray, for example, I would get one," Black said, claiming that he regularly refuses imaging at the dentist's office. "But the reflex to get one every year is overexposing one to X-rays. And these are going to the base of the brain, toward the base of the skull."

The new findings are important because dental X-rays are the most common source of exposure to ionizing radiation among residents of the United States, according to the study's authors. And while they write that full-mouth and bitewing X-rays are associated with lower levels of exposure than other types of medical imaging, the No. 1 environmental -- and generally modifiable -- risk factor for meningioma is exposure to ionizing radiation.

"It's hard to define a threshold because it's very complex frequency and dosing equations go into that," Black said. "We just need to be more aware of the risk and try to limit the use."

Read more: [http://www.huffingtonpost.com/2012/04/10/dental-x-rays-brain-tumor\\_n\\_1413158.html](http://www.huffingtonpost.com/2012/04/10/dental-x-rays-brain-tumor_n_1413158.html)

(Lexile Measure: 1530L)